

院訊 News *Letter*

Apr – Oct 2021

vol.

109

第一百零九期

齊服務 展關懷 WE SERVE & WE CARE

Medical article

Is There Light at the End of the Tunnel?

Pharmaceutical update:
**Overview of Herpes
Zoster Vaccines**



聖保祿醫院
St. Paul's Hospital

MESSAGE

FROM THE CHIEF MEDICAL EXECUTIVE



Dr. William Ho
Chief Medical Executive

With Hong Kong persistently implementing one of the most stringent set of measures in the world in tackling COVID-19, zero local cases had been practically achieved over the past five months since end of April, apart from a few isolated ones which were swiftly contained. The same cannot be said across the world, where outbreaks rapidly resumed once measures were relaxed, particularly in the USA, UK, and even Singapore. With the Delta variant still running rampant and many countries opting for “living with the virus”, it is likely that the risk to our society will continue for months if not years. While scientific advances have enabled the light-speed development and manufacture of effective vaccines, they are generally less effective in preventing transmission than preventing severe illnesses and deaths. To complicate the matter, vaccine hesitancy is still a major problem, sadly also true in Hong Kong among the elderly who actually need its protection most. In our hospital, vaccination rate has surpassed 90% among all staff, and 100% among doctors. The convenience of a vaccination centre right inside the hospital certainly helped. In my encounter with visiting doctors, again almost everyone got vaccinated. Our Infection Control Committee and Emergency Task Force on COVID-19 are continually monitoring the situation and responding to the frequent changes in government policy regarding quarantine/testing requirements for returnees etc. Suffice it to say that at the moment, a high degree of vigilance is still needed, and there is little room to relax the relevant control measures that have been put in place.

We are happy to see the return of hospital activities back to or even exceeding pre-COVID periods, especially in endoscopies, cardiac work and radiological examinations. The bottle neck on service expansion now is really manpower, especially nursing. There are the combined challenges of emigration and recruitment competition from other private hospitals including the new one. It will be a while before the dust settles. Meanwhile, we are working hard on improving internal workflow and efficiency, as well as listening to staff for their constructive suggestions. The Community Vaccination Centre will have completed its historical mission by the end of this month, by which time the held-up manpower can be released to the wards.

The final phase of our Hospital Redevelopment Project continues smoothly, which however will at times produce unavoidable noise nuisance, and we thank everybody for your tolerance and understanding. Upon its completion, we will have opportunities to further shuffle around functions to further improve operational flow, customer experience, and have a nice garden leading up to the magnificent Christ the King Chapel, flanked by the two major blocks. For now, we eagerly look forward to seeing the end of the tunnel in the COVID-19 pandemic. We pray for the help and mercy of Almighty God to deliver the world out of such darkness, while patiently and diligently continue to serve the community and those in need under all circumstances.



Dr. Lee Yin Yin, Candice
Staff Consultant in Respiratory Medicine
St. Paul's Hospital

Is There Light at the End of the Tunnel?

The COVID-19 pandemic has exploded since cases were first reported in China in December 2019. As of 1 July 2021, more than 182 million cases of COVID-19 have been reported, among which there were more than 3.9 million deaths¹. Individuals of all ages are at risk for SARS-CoV-2 infection and severe disease. However, the probability of serious COVID-19 disease is higher in people aged ≥ 60 years, those living in institutions, and those with chronic medical conditions. Of all confirmed cases in USA around 14% of patients required hospitalization, 2% were admitted to the intensive care unit, and 5% died². The percentage of patients who died was 12 times higher among those with reported medical conditions (19.5%) than among those without medical condition (1.6%). The mortality rate was highest in those aged >70 years, regardless of the presence of chronic medical conditions³.

The estimated incubation period for COVID-19 is up to 14 days from the time of exposure, with a median incubation period of 4 to 5 days⁴. The spectrum of illness can range from asymptomatic infection to severe pneumonia with acute respiratory distress syndrome and death. Among 72,314 persons with COVID-19 in China, 81% of cases were reported to be mild, 14% were severe and 5% were critical⁵.

Two main processes are thought to drive the pathogenesis of COVID-19. Early in the clinical course, the disease is primarily driven by the replication of SARS-CoV-2. Later in the clinical course, the disease appears to be driven by a dysregulated immune/inflammatory response to SARS-CoV-2 that leads to tissue damage. Based on this understanding, it is anticipated that therapies that directly target SARS-CoV-2 would have the greatest effect early in the course of the disease, while immunosuppressive/anti-inflammatory therapies are likely to be more beneficial in the later stages of COVID-19.

Approximately 80% of patients with COVID-19 have mild illness (defined as the absence of viral pneumonia and hypoxemia) that does not warrant medical intervention or hospitalization. Mild COVID-19 cases can be managed in an ambulatory care setting with as needed symptomatic treatments e.g. hydration, antipyretic and analgesics, etc. Moderate COVID-19 (those with viral pneumonia but without hypoxemia) or severe COVID-19 (those with dyspnea, hypoxemia, or lung infiltrate $\geq 50\%$) need hospitalization and close monitoring.

Remdesivir, an intravenous nucleotide prodrug of an adenosine analog, is currently the only drug that is approved by the FDA for the treatment of COVID-19. It is recommended for use in hospitalized patients who require supplemental oxygen⁶. Remdesivir binds to the viral RNA-dependent RNA polymerase and inhibits viral replication through premature termination of RNA transcription. It has demonstrated in vitro activity against SARS-CoV-2. The dose for remdesivir is 200mg IV for one dose, followed by remdesivir 100mg IV once daily for 4 days or until hospital discharge.

For patients who require increasing amount of oxygen, the combination of dexamethasone plus remdesivir is often used in hope to mitigate and dampen the potentially injurious inflammatory response that is a consequence of the infection. Dexamethasone was shown to reduce mortality in hospitalized patients with COVID-19 who required supplemental oxygen in the RECOVERY

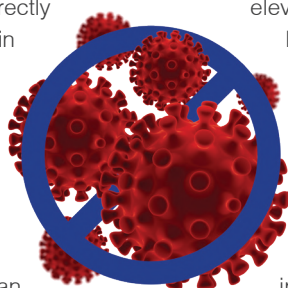
trial⁷. The dose for dexamethasone is 6mg IV or PO once daily for 10 days or until hospital discharge.

In selected cases who require invasive mechanical ventilation or even extracorporeal membrane oxygenation, dexamethasone plus tocilizumab, an interleukin (IL)-6 inhibitor, may be beneficial if given within 24 hours of admission to the ICU, according to the REMAP-CAP and RECOVERY trials⁸⁻⁹. Interleukin (IL)-6 is a pleiotropic, proinflammatory cytokine produced by a variety of cell types, including lymphocytes, monocytes, and fibroblasts. COVID-19 associated systemic inflammation and hypoxic respiratory failure can be associated with heightened cytokine release, as indicated by elevated blood levels of IL-6, C-reactive protein (CRP), D-dimer, and ferritin. It is hypothesized that modulating the levels of IL-6 or its effects may reduce the duration and/or severity of COVID-19 illness. This combination of dexamethasone and tocilizumab, however, may increase the risk of opportunistic infections or reactivation of latent infections.

Other treatment modalities currently being researched include anti-SARS-CoV-2 monoclonal antibodies, COVID-19 convalescent plasma, anti-SARS-CoV-2 specific immunoglobulin, etc. But despite all these available treatments the COVID disease still causes significant morbidity and mortality. It is with hope that ongoing research in both treatment and vaccination will eventually bring this devastating pandemic under control.

References:

1. Johns Hopkins. COVID-19 Dashboard by the Center for Science and Engineering. 2021
2. Stokes EK, Zambrano LD, Anderson KN, et al. Coronavirus disease 2019 case surveillance—United States, January 22–May 30, 2020. *MMWR Morb Mortal Wkly Rep.* 2020;69.
3. Garg S, Kim L, Whitaker M, et al. Hospitalization rates and characteristics of patients hospitalized with laboratory-confirmed coronavirus disease 2019—COVID-NET, 14 states, March 1–30, 2020. *MMWR Morb Mortal Wkly Rep.* 2020;69(15):458-464.
4. Guan WJ, Ni ZY, Hu Y, et al. Clinical characteristics of coronavirus disease 2019 in China. *N Engl J Med.* 2020 30;382(18):1708-1720.
5. Wu Z, McGoogan JM. Characteristics of and important lessons from the coronavirus disease 2019 (COVID-19) outbreak in China: summary of a report of 72,314 cases from the Chinese Center for Disease Control and Prevention. *JAMA.* 2020;323(13):1239-1242.
6. Beigel JH, Tomashek KM, Dodd LE, et al. Remdesivir for the treatment of COVID-19—final report. *N Engl J Med.* 2020;383(19):1813-1826.
7. RECOVERY Collaborative Group, Horby P, Lim WS, et al. Dexamethasone in hospitalized patients with COVID-19—preliminary report. *N Engl J Med.* 2021;384(8):693-704.
8. REMAP-CAP Investigators, Gordon AC, Mouncey PR, et al. Interleukin-6 receptor antagonists in critically ill patients with COVID-19. *N Engl J Med.* 2021;384(16):1491-1502.
9. RECOVERY Collaborative Group. Tocilizumab in patients admitted to hospital with COVID-19 (RECOVERY): a randomised, controlled, open-label, platform trial. *Lancet.* 2021;397(10285):1637-1645.



Overview of Herpes Zoster Vaccines

SPH Pharmacy Department

Introduction

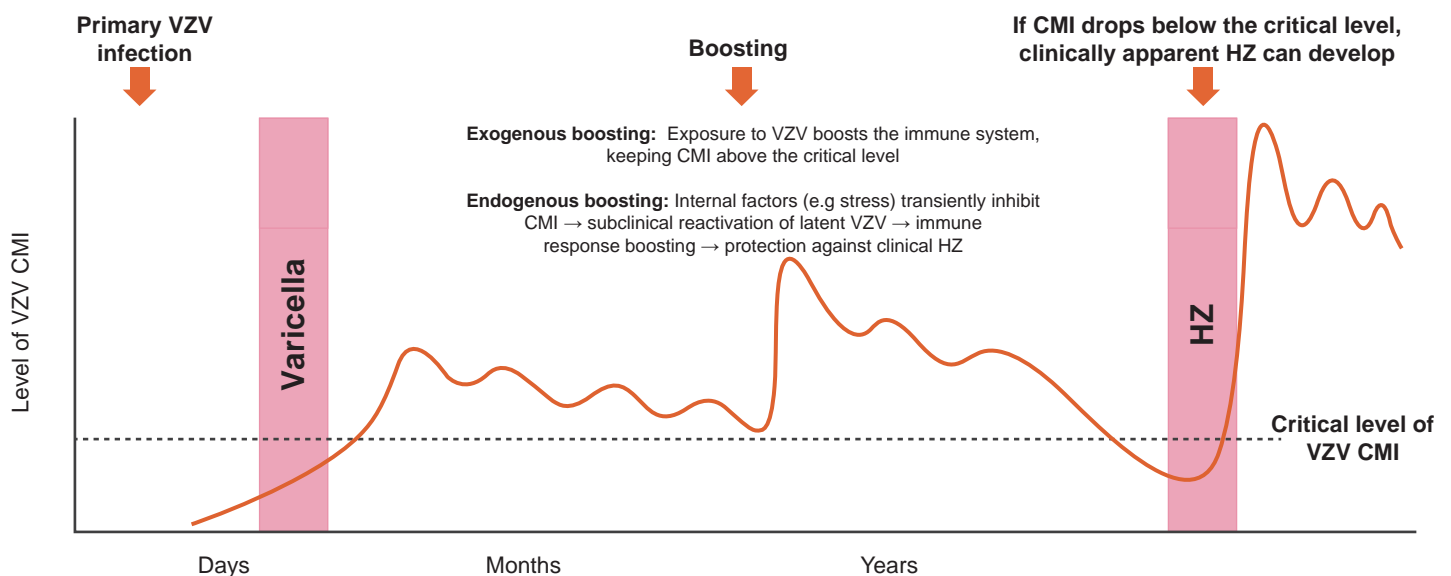
Herpes zoster, commonly known as shingles, is a disease caused by the reactivation of latent Varicella Zoster Virus (VZV). Patients with herpes zoster often present with dermatomal rashes accompanied with blisters, vesicular eruptions, and neuropathic pain. Although it is often self-limiting, occasionally patients may experience neural and ophthalmic complications, such as post-herpetic neuralgia, facial paralysis, and herpes zoster ophthalmicus. Up to 3% of patients even require hospitalization.¹

Epidemiology

In Hong Kong, over 8000 cases of herpes zoster were reported in 2016. A survey conducted by the University of Hong Kong showed that 16.8% of Hong Kong population recalled having at least one episode of herpes zoster in their life, with an increased percentage for the populations above 60 and 70.²

Any patients with a history of primary VZV infection, as known as chickenpox, or who received VZV vaccinations in the past are at risk of developing herpes zoster. The virus remains latent in patients' body, which can be reactivated anytime. Nevertheless, patients who received VZV vaccination tended to have a lower risk of herpes zoster compared to those with chickenpox.³

One of the major risk factors for herpes zoster is declining in VZV-specific cell-mediated immunity resulting from advancing age and from medical conditions or medications that suppress a person's immunity such as patients with cancers or Human Immunodeficiency Virus (HIV) infections, or those who require long-term immunosuppressants such as organ transplant recipients.³ The relationship between cell-mediated immunity with time was proposed by Hope-Simpson in 1965 as illustrated in Figure 1.⁴



HZ, herpes zoster, VZV, varicella zoster virus, CMI, cell-mediated immunity.

Figure 1. VZV Cell-mediated Immunity Levels over Time (adapted from Wutzler et al.)⁴

Overview of Herpes Zoster Vaccines

Currently, Zostavax[®] and Shingrix[®] are the two available vaccines for preventing herpes zoster, which were registered in Hong Kong in March 2007 and September 2020 respectively. They are both approved by the U.S. Food and Drug Administration (FDA) for use in patients aged above 50. However, Zostavax[®] is no longer available in the U.S. since July 2020 due to the manufacturer's discontinuation.

Zostavax[®] (Zoster Vaccine Live), is a live-attenuated vaccine that granted FDA approval in 2006. It was shown to have an efficacy of 69.8% in preventing herpes zoster in patients aged 50-59. Nonetheless, the major limitation of the vaccine is a significant decrease in efficacy as the age of patients increases. For patients aged between 70-79, Zostavax[®] only conferred 41% risk reduction, and it dropped to 18% for patients aged above 80. Moreover, as Zostavax[®] is a live-attenuated vaccine, use in immunocompromised patients and pregnant women is contraindicated.⁵ As elderly and immunocompromised patients are at higher risk of developing herpes zoster, newer vaccines are required to address the need. A recent review in June 2021 by Therapeutic Goods Administration (TGA) of Australia also warned for the potential risk of disseminated VZV infection with the use of Zostavax[®]. The risk increases with degree of immunosuppression, and fatal reports had been identified.⁶

A newer vaccine, Shingrix[®] (Recombinant Zoster Vaccine) is a recombinant vaccine which granted FDA approval in 2017. After reconstitution, the VZV antigen in the vaccine combines with an adjuvant system. The adjuvant was shown to enhance VZV-specific immunity in non-clinical data. Indeed, results from two large studies (ZOE-50 and ZOE-70) showed that it can reduce herpes zoster by 96.6%, 97.4% and 91.3% in patients aged 50-59, 60-69 and >70 respectively, which is higher than that of Zostavax[®] in all ages. The difference in efficacy between the two vaccines was most pronounced among recipients aged ≥70 years.⁷ Unlike Zostavax[®] which only requires a single-dose, Shingrix[®] requires two doses (2-6 months apart) for obtaining full efficacy. Although costs may be a concern for the 2-dose Shingrix[®] series, it was found to be more cost effective than Zostavax[®] based on most cost effectiveness analysis.^{8, 9, 10} Additionally, a recent post-marketing observational study carried out by FDA in March 2021 showed an increased risk of Guillain-Barré Syndrome (GBS) during the 42 days following the first dose of vaccination, with 3 to 6 excess cases of GBS per million doses administered to adults aged 65 or above.¹¹

The latest recommendations of the Advisory Committee on Immunization Practices (ACIP) of the U.S. favored the use of Shingrix[®] over Zostavax[®] by considering efficacy against herpes zoster and post-herpetic neuralgia. Although both vaccines are indicated for adults aged above 50, ACIP did not recommend the use of Zostavax[®] in patients aged 50-59. As the vaccine efficacy wanes within the first 5 years after vaccination, and the protection beyond 5 years cannot be warranted; therefore long-term protection is uncertain when adults receiving the vaccine before age 60 years when their risks for herpes zoster and its complications are highest.¹²

Despite the presence of two vaccines for herpes zoster, some questions are needed to be addressed. The duration of protection for the two vaccines is still uncertain and the need of re-vaccination has not been fully determined. For Zostavax[®], studies concur that there is a substantial decrease in effectiveness following the first year after receipt of the vaccine and, by 6 years postvaccination, vaccine effectiveness against herpes zoster is <35% and dropped to 21-32% during years 7-8 postvaccination. Estimates of effectiveness were no longer statistically significant 9-11 years postvaccination in the longest study of Zostavax[®]. For Shingrix[®], data to date indicate the duration of protection following the 2-dose series of recombinant zoster vaccine is at least 4 years. Studies on assessing its long term effectiveness are still lacking.¹³ However, ACIP states that Shingrix[®] is likely to provide substantial protection against zoster for more than 4 years. In addition, immunocompromised persons and those on moderate to high doses of immunosuppressants were excluded from the efficacy studies of Shingrix[®] (ZOE-50 and ZOE-70), the effectiveness and safety in this population group remained uncertain.⁷

For the prevention of post-herpetic neuralgia in patients with confirmed herpes zoster, as shown in separate clinical trials for all age categories, Shingrix[®] estimates of efficacy against herpes zoster were higher than those for Zostavax[®]. Estimates of efficacy against post-herpetic neuralgia are also higher for Shingrix[®] than for Zostavax[®]. Zostavax[®] efficacy wanes substantially during the 4 years following receipt. As a result of higher and more long-lasting efficacy, Shingrix[®] is estimated to prevent more herpes zoster and postherpetic neuralgia compared with Zostavax[®].¹³

	Shingrix [®]			Zostavax [®]			
Age group	50-59	60-69	≥70	50-59	60-69	70-79	≥80
Herpes Zoster risk reduction	96.6%	97.4%	89.8%	70%	64%	41%	18%
Post-herpetic neuralgia risk reduction	Age ≥ 50: 100%		88.8%	Unknown	5%	55%	26%

Table 1. Efficacy of Shingrix[®] and Zostavax[®] ^{7, 13}



Vaccine	Recombinant Zoster Virus (RZV) (Shingrix®) 	Zoster Vaccine Live (ZVL) (Zostavax®) 
Registration date in Hong Kong	September 2020	March 2007
Vaccination type	Recombinant glycoprotein E vaccine	Live-attenuated vaccine
Manufacturer	GSK	MSD
Dose & schedule	Adults aged ≥50 years old: Two doses of 0.5mL each 1 st dose: Day 0 2 nd dose: 2-6 months after the 1 st dose	Adults aged ≥50 years old: One single dose of 0.65mL
Route of administration	Intramuscular in deltoid muscle	Subcutaneous
Contraindications	<ul style="list-style-type: none"> Severe allergic reactions (e.g. anaphylaxis) to varicella virus vaccine, or after a previous dose of Shingrix® 	<ul style="list-style-type: none"> Severe allergic reactions (e.g. anaphylaxis) to varicella virus vaccine, neomycin, gelatin (history of contact dermatitis due to neomycin is not a contraindication) Immunocompromised (e.g. symptomatic HIV, on high dose systemic steroids)
Adverse reactions	<ul style="list-style-type: none"> Median duration of reactions: 3 days Injection site pain (68.1%), myalgia (32.9%), fatigue (32.2%), headache (26.3%) An increased risk of GBS was observed during the 42 days following vaccination¹¹ 	<ul style="list-style-type: none"> Injection site pain (48%), headache (9.4%), pain in the extremity (1.3%) Reports of fetal disseminated VZV infection identified in patients, including in patients on low dose immunosuppressants
Pregnancy/ Breastfeeding	<ul style="list-style-type: none"> No human data available CDC recommendation (2018): Avoid if currently are pregnancy or breastfeeding¹³ 	<ul style="list-style-type: none"> Contraindicated in pregnant women Avoid pregnancy for 3 months following vaccination
Other concerns	<ul style="list-style-type: none"> No recommendations available in immunocompromised patients, or those who are receiving moderate to high dose immunosuppressants (i.e. ≥20 mg/day of prednisone or equivalent)¹² 	<ul style="list-style-type: none"> Discontinued in the U.S. since July 2020

Table 2. Comparison of Shingrix® and Zostavax®^{7, 13}

Practical Tips for the Usage of Herpes Zoster Vaccines

1. Q: Should patients aged below 50 receive herpes zoster vaccines?

There is insufficient information to determine the risk and benefits of administering herpes zoster vaccines in patients aged below 50, it is not recommended by FDA.¹³

2. Q: Can patients receive herpes zoster vaccines if they have prior episode(s) of herpes zoster infection?

Persons with a history of previous episode of herpes zoster can be given Shingrix® or Zostavax®. However, patients with an acute episode of herpes zoster should not receive the vaccine. There is no specific timing of vaccination in these populations, but FDA recommends waiting until the resolution of acute infection and subsidence of symptoms.¹³

3. Q: Could patients receive Shingrix® if they have received Zostavax® before?

Shingrix® may be used in adults aged ≥50 years, irrespective of prior receipt of varicella vaccine or Zostavax®. Whereas, the optimal timing of revaccination is unclear. Studies have examined the safety and immunogenicity of Shingrix® vaccination administered ≥5 years after Zostavax®; yet shorter intervals have not been studied. However, a shorter interval may be considered based on the recipient's age when Zostavax® was administered. ACIP recommends a minimal 8-week interval between Zostavax® vaccination and the first dose of Shingrix® based on expert opinions.¹³

4. Q: Can patients concomitantly receive other vaccines with Zostavax® or Shingrix®?

Shingrix®, a recombinant and adjuvanted vaccine, can be given concurrently with other unadjuvanted inactivated seasonal influenza vaccine, Pneumovax-23® or dTpa vaccine⁷ at different anatomic sites based on CDC's general best practice guidelines. Zostavax®, a live attenuated vaccine, should be either administered simultaneously or be separated for at least 28 days with other live vaccines (e.g. intranasal influenza vaccines (LAIV), MMR, yellow fever and etc). Regarding the co-administration with Pneumovax-23®, the manufacturer of Zostavax® recommends administering 4 weeks apart as concomitant administration results in a lower VZV antibody level.⁵

5. **Q: Is the Shingrix® series needed to be repeated if the administration of second dose is deviated from the recommended 2-6 months after the first dose?**

The vaccine series do not need to restart if more than 6 months have elapsed since the first dose; however, the efficacy of alternative dosing regimens has not been evaluated, data regarding the safety of alternative regimens are limited.

Pharmacists’ Point of View

Herpes zoster is very common in Hong Kong and it can adversely impact patients’ health and quality of life. Some patients may even have to be hospitalized due to complications. Although the disease can often be treated with antivirals, it requires patients to seek medical help within 72 hours to achieve maximal efficacy. Besides, the complications, especially post-herpetic neuralgia, may not be resolved immediately after treatment, which brings nuisances to patients’ daily life. Vaccination is a safe and effective strategy to prevent herpes zoster. Despite a higher efficacy demonstrated by Shingrix®, patients’ preferences should also be considered due to a different dosing regimen and different side effects profile. Zostavax® and Shingrix® are both available in St. Paul’s Hospital.

References:

1. Cohen, J. I. (2013). Herpes zoster. *New England Journal of Medicine*, 369(3), 255-263.
2. Lam, A. C., Chan, M. Y., Chou, H. Y., Ho, S. Y., Li, H. L., Lo, C. Y., ... & Yeung, I. (2017). A cross-sectional study of the knowledge, attitude, and practice of patients aged 50 years or above towards herpes zoster in an out-patient setting. *Hong Kong medical journal*, 23(4), 365-373.
3. Shingles (Herpes Zoster). Centers for Disease Control and Prevention. (2020).
4. Wutzler, P., Casabona, G., Cnops, J., Akpo, E. I. H., & Safadi, M. A. P. (2018). Herpes zoster in the context of varicella vaccination – An equation with several variables. *Vaccine*, 36(46), 7072-7082.
5. ZOSTAVAX. Product monograph. MSD.
6. Safety measures to address risk of infection with the vaccine virus. Therapeutic Goods Administration (TGA). (2021).
7. SHINGRIX. Product monograph. GSK.
8. Prosser, L. A., Harpaz, R., Rose, A. M., Gebremariam, A., Guo, A., Ortega-Sanchez, I. R., ... & Dooling, K. (2019). A cost-effectiveness analysis of vaccination for prevention of herpes zoster and related complications: input for national recommendations. *Annals of internal medicine*, 170(6), 380-388.
9. Le, P., & Rothberg, M. B. (2018). Cost-effectiveness of the adjuvanted herpes zoster subunit vaccine in older adults. *JAMA internal medicine*, 178(2), 248-258.
10. Leidner, A. J. (2017). Overview of two economic models that assess the cost-effectiveness of herpes zoster vaccinations.
11. FDA Requires a Warning about Guillain-Barré Syndrome (GBS) be Included in the Prescribing Information for Shingrix. U.S. Food and Drug Administration. (2021).
12. Harpaz, R., Ortega-Sanchez, I. R., & Seward, J. F. (2008). Prevention of herpes zoster: recommendations of the Advisory Committee on Immunization Practices (ACIP). *Morbidity and Mortality Weekly Report: Recommendations and Reports*, 57(5), 1-30.
13. Dooling, K., Guo, A., Patel, M., Lee, G., Moore, K., Belongia, E., & Harpaz, R. (2018). Recommendations of the Advisory Committee on Immunization Practices for Use of Herpes Zoster Vaccines. *MMWR. Morbidity And Mortality Weekly Report*, 67(3), 103-108.



NEW DRUG APPROVAL

Following Drug and Therapeutics Committee meeting in August 2021, the following drugs have been approved and added to the formulary at SPH:

Drugs	Indication (s)	Usual dosage	Remarks
Staquis (crisaborole) ointment 2%	Treatment of mild-to-moderate atopic dermatitis in patients 2 years of age and older	Apply a thin film to affected area(s) twice daily	On request only
Dayvigo (lemborexant) tablet 5mg	Treatment of adult patients with insomnia, characterized by difficulties with sleep onset and/or sleep maintenance	<ul style="list-style-type: none"> • Take 5mg once per night, immediately before bedtime, with at least 7 hours remaining before the planned time of awakening • Maximum dose: 10mg per day 	Time to sleep onset may be delayed if taken with or soon after a meal
Phenylalpha (phenylephrine hydrochloride) pre-filled syringe 500mcg/10mL	Treatment of hypotension during spinal, epidural or general anaesthesia	<ul style="list-style-type: none"> • IV bolus injection • 50 - 100mcg, which can be repeated until the desired effect is attained (each bolus dose should not exceed 100mcg) 	N/A

Strawberry milk in early postpartum

SPH Nursery Department

Strawberry milk---- my favourite drink. Many people like this pink sweet lovely drink too, especially in this hot summer. However, if it appears in the breastmilk, this is another story. I would like to share my experience in supporting a mother having early onset strawberry milk in the postnatal ward of a private hospital.

Mrs. C, a 35 years old first-time mother, was very keen on breastfeeding. She went through Caesarean Section because of her baby in breech presentation. On the first post-natal day, she started to hand express the breastmilk. However, she was much astonished when she found her expressed breastmilk looked rusty brown instead of golden yellow. It persisted whenever she expressed her breastmilk from either breast. Very soon, the obstetrician came to assess her and arranged her some investigation. At the same time, she was recommended to stop breastfeeding while waiting for the investigation result. She was very worried and sought help from me.

My consultation with Mrs. C found that this was her first episode of brown nipple discharge. She did not experience any pain or discomfort when expressing the breastmilk. She did not have any history of pain, trauma or recent infection to her breasts. She had had her body check including a mammogram just before this pregnancy, which was normal. She had no family history of breast cancer. Examination of the breasts revealed no engorgement, tenderness and erythema. The nipples and areola looked normal without any erosions, ulcers and cracks. My presumptive diagnosis was a relatively rare but benign condition, Rusty Pipe Syndrome.

What is Rusty Pipe Syndrome (RPS)?

This term was first used at a La Leche League conference in 1990 by Chele Marmet. This name comes from the breastmilk appearance of rusty water from old pipes. Typically, a lactating mother presents with painless bilateral, sometimes unilateral, blood stained breastmilk in early postpartum which generally resolves within a few days. It is more common in mothers expressing breastmilk than those breastfeeding directly, partly because the latter may remain unnoticed. Occurrence is in the early stage of lactogenesis i.e. in early postpartum, sometimes late pregnancy and is more common in primigravida. It is thought to be caused by increased vascularization of the rapidly developing alveolae and ducts of mammary tissues. As they can be easily traumatized, blood may escape into the milk secretion causing rusty brown appearance.²

In the early stage of lactogenesis, the gap between milk-secreting cuboidal cells lining the alveolae, is large.



Antibodies and nutrients of bigger molecular size can escape from the blood stream into the colostrum. This explains why colostrum is rich in immunoglobins which are mega molecules. As the cuboidal cells swell up under the influence of prolactin, these large intercellular gaps gradually close day after day, stopping larger molecules from entering into the breastmilk. The usual milky colour of breastmilk then appears.

Prevalence of Rusty Pipe Syndrome

The earliest published study was by Merlob and colleagues¹ in 1990 when 7774 live births in Israel were studied prospectively for 2 years. Eight mothers reported atypical breast discharge, characterized by early appearance of atypical colour but normal cytology and bacteriology. It became normal milk colour without reappearance of atypical breastmilk in 2-5 days which signify an important differentiating feature from other pathological breast lesions. All had no adverse effects on the mothers and their babies. The prevalence rate was about 0.1% (1 out of 971 live births).

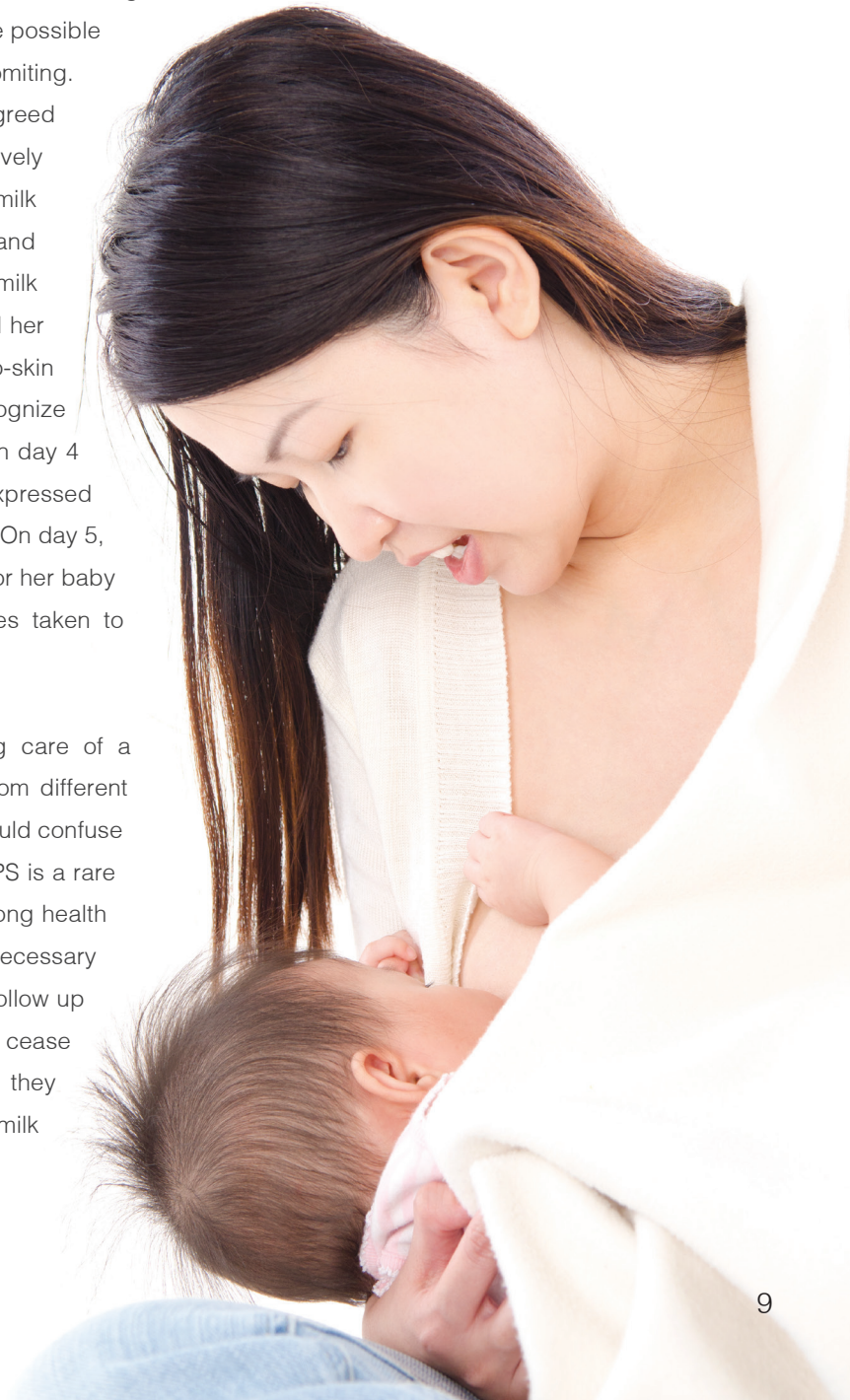Management for the Mother with Rusty Pipe Syndrome

RPS is a relatively rare clinical entity. Many health care workers may not have encountered it before, not to say lactating mothers in the general public. Being a clinician promoting breastfeeding, we play an important role in supporting the mother as well as liaising with other health care members.

The most common cause of blood in breastmilk is a cracked nipple. A less common condition that may cause blood in breastmilk is an intraductal papilloma — a small benign wart-like growth on the lining of a milk duct, which bleeds. Although this lesion is not malignant and usually resolves in a few days, medical evaluation is needed. Diagnosis of RPS is usually made by a typical history, a normal physical examination, followed by complementary examinations such as breastmilk cytology and ultrasonography of the breasts, if indicated. In this mother, there is a usual RPS manifestation together with a normal physical examination and a normal mammogram one year before. Conservative management was therefore adopted.

Mrs. C was counselled. We had a discussion on the cause and natural course about RPS. We talked about the harmless effect on the baby when taking a small amount of serosanguineous discharge as well as the possible irritation to the baby's stomach causing regurgitation or vomiting. She felt more relieved. She finally decided to follow the agreed plan to continue expression, observe the progress and actively prepare for direct breastfeeding. She expressed her breastmilk every 3 hours and stored them in serial bottles (see Photo 1 and 2). She was further reassured as the red-tinted breastmilk gradually faded day by day. At the same time, she cup-fed her baby with formula milk. She frequently held her baby skin-to-skin to build their bonding as well as facilitating her baby to recognize her smell to help the attachment. She had milk comes-in on day 4 postpartum when the bleeding had largely ceased. The expressed milk became golden yellow, the typical colour of colostrum. On day 5, the mother started direct breastfeeding. It didn't take long for her baby to learn the attachment skill because of all the measures taken to facilitate the switch to direct breastfeeding.

Collaboration with other health care professionals taking care of a lactating mother is as important.³ Advice to the mother from different professionals may be diverse or even contradicting. This would confuse the mother and defeat her confidence in breastfeeding. RPS is a rare physiological self-limiting condition. Knowledge of RPS among health professionals would be very helpful to avoid unnecessary investigation and preclude anxiety in mothers. We should follow up these mothers closely and support them not to cease breastfeeding in the early stage. If the bleeding continues, they should be medically evaluated. Once the red-tinted breastmilk faded, we should facilitate direct breastfeeding.



Conclusions

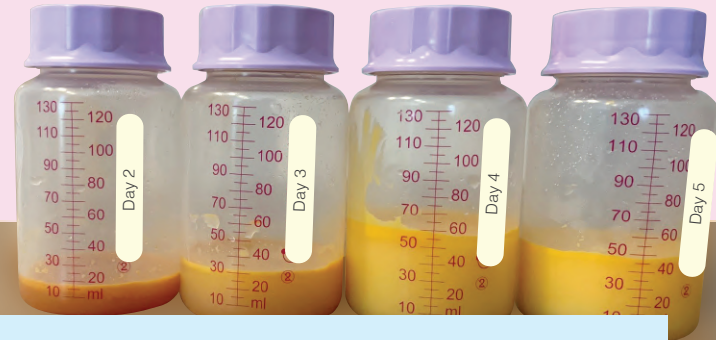Bleeding in breastfeeding is alarming. Suggesting a mother to quit breastfeeding too early should always be avoided. As health care professionals, we have to analyse the situation by taking a thorough history, examining the breasts, checking breastfeeding skills / expression technique as well as offering psychological support to the mother. Giving correct information are crucial in helping her get out from fear and make an informed choice. Discussing and planning with her can facilitate her engagement in every step towards the final goal of exclusive breastfeeding.



Photo 1: expressed breastmilk in postpartum day 1
With permission from St. Paul's Hospital

Photo 2:

expressed breastmilk from day 2 to day 5 postpartum With permission from St. Paul's Hospital



References:

1. Merlob P, Aloni R, Prager H, Mor N, Litwin A. Blood-stained maternal milk: prevalence, characteristics and counselling. Eur J Obstet Gynecol Reprod Biol. May-Jun 1990;35(2-3):153-7.
2. Sabate JM, Clotet M, Torrubia S, Gomez A. Radiologic Evaluation of Breast Disorders Related to Pregnancy and Lactation. RadioGraphics. 2007;27, No. Suppl_1
3. Bahar Kural, Serap Sapmaz. Rusty Pipe Syndrome and review of literature. Breastfeeding Medicine. Volume 15, Number 9, 2020

INTRODUCTION


OF NEW FACES

Hi friends & colleagues, this is Oscar Chan. I am so glad to have an opportunity to help develop the oncology service in St. Paul's hospital. As you may aware, the incidence of cancer in HK is rising steadily at 2-3% per annum. There is a growing demand of high-quality cancer service. And I trust a well-equipped oncology centre will add great value to SPH.

After my graduation in CUHK in 2001, I started my specialist training at Pamela Youde Nethersole Eastern Hospital. My special focus is in lung, head and neck cancers and the application novel RT technique in oligometastases. I am a strong advocate in clinical trials. In the past 20 years, I have participated in multiple local or global international trials and have contributed over 40 articles/ meeting abstracts in international journals, conferences & book chapters. Looking forward to collaborating with you all in the near future!



Dr. Chan Siu Hong
Hon. Director of Oncology Services




Dr. Tse James Chi Hon
Specialist in Radiologist

Hello, it is my pleasure to join the St. Paul's family as a new radiologist. I started my career at Pamela Youde Nethersole Eastern Hospital and completed my training there, during which I went overseas for training on interventional radiology in Asan Medical Center, Seoul, Korea. It was one of my most memorable experiences and I really enjoyed it. Prior to joining St Paul's, I also worked at Union Hospital for about two years. I have special interest in body and neuroradiology imaging. Apart from work, I also enjoy good food, movies and basketball. I look forward to collaborating and providing the best care to our patients with you all in the future.

It's my pleasure to enter the St. Paul work community. I started my employment since July and I think I have already met some of the team members personally. I am looking forward to collaborating work with all of you.

I am a family physician and finished my training as a fellow in Monash University Melbourne. As a GP, I worked in different community setting both in Australia and Hong Kong. So far I have been in HK for more than 15 years. I worked in clinics, counselling clinics, family planning clinics, hospitals and government settings seeing patients from different levels, dealing with various aspects of care. I found that team work spirit is the key for treatment success for our patients. I am looking forward to any teamwork building activities ahead.



Dr. Chan Ming Tat
Resident Medical Officer