

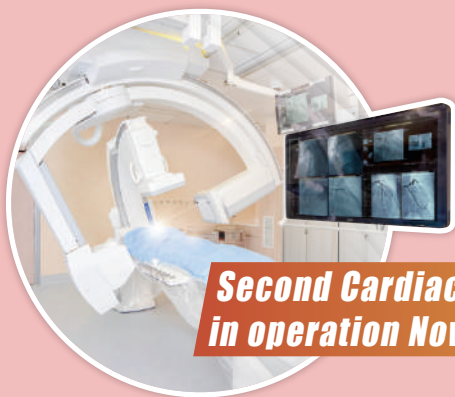


守得雲開見月明
揚眉「兔」氣迎新景

Surgical management of



axilla in **BREAST CANCER** patient



**Second Cardiac Catheterization Laboratory
in operation November 2022**

Pharmaceutical update
**Management of
drug-drug interactions in
oral anticancer drugs**



聖保祿醫院
St. Paul's Hospital

修女^福的話

守得雲開見月明 揚眉「兔」氣迎新景

兔年又來臨了，在此我先恭祝各位
身壯力健、工作順利、主寵日隆！

新的一年，又是時候規劃一下人生，想想未來一年、五年、十年應該完成的目標是甚麼？有人訂下目標後，會積極進取、無懼艱辛地達成夢想。相反，有人會思前想後，畏首畏尾，最終可能目標未達成，便憂鬱得病倒了。你會是那一種人呢？

過去三年的疫情，香港人都過得很不容易，相信不少人都是活在焦慮中。起初由搶購口罩變成囤積口罩；由研製疫苗至到有多種疫苗推出，由怕疫苗副作用至現時有超過八成的香港人已接種第三劑新冠疫苗……這一切全是過程。人結果都是繼續生活，繼續工作，繼續可以跟朋友相聚。我所說的，不是叫大家逆來順受，而是希望大家想想，無論在順境逆境，我們應該是以甚麼心態去看待。要知道，我們是無法掌管明天的。

瑪竇福音第六章第34節是這樣說的：「所以你們不要為明天憂慮，因為明天有明天的憂慮！一天的苦足夠一天受的了。」

候鳥從北方飛往南方的時候，雖然不知道目的地在那裡，但是牠們還是堅持一直飛。牠們不會掛慮路途有多遙遠，也不會掛慮新居會是怎樣，可是，世人每天卻常常擔憂明天的事，怕退休後錢不夠用，憂心自己健康狀況變差，又擔心子女長大後會離開自己，有時候，對自己和未來也缺乏信心，其實，這些憂慮都是為你的心靈和思想增加不必要的重擔。我們何不效法基督耶穌，依賴創造天地萬物的上主呢？耶穌在山園祈禱時，縱使知道自己即將要為世人犧牲，但仍然選擇捨棄自我的執著，順從主的旨意，把一切都交託祂手中，因為耶穌深信天主自有計劃。同樣，世人應當對天主有信心，因為即使明天的路有多難走，天主也會給予力量我們面對困難。世事難料，唯盼天主的帶領和安排。所以我們應常喜樂，不斷祈禱，事事感恩。

就讓我們懷著信心和希望活好已知的今天，把心中的悶氣、憂鬱也釋放出來，以迎接新的一年。讓我再次祝福大家新的一年心想事成，幸福年年，主佑各位！

張柱見修女



Dr. William Ho
Chief Medical Executive

Turning a New Page

Kung Hei Fat Choy to everybody!

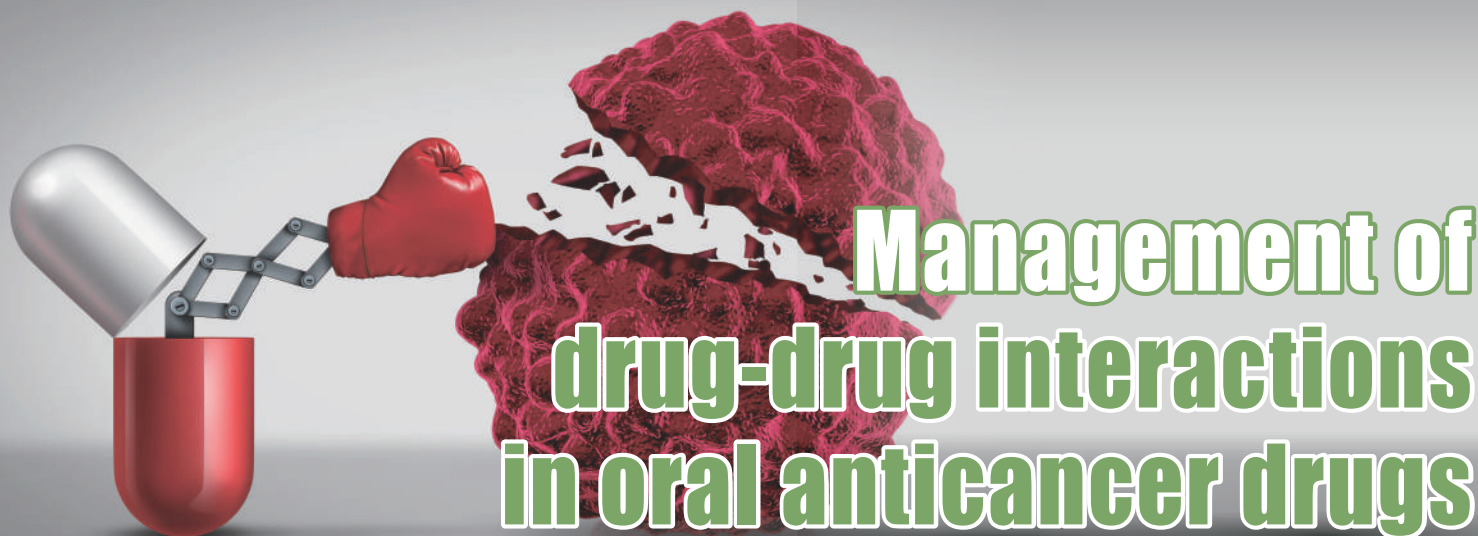Let's first pray that the Year of the Rabbit will herald a final ending of the ordeal that haunted us for three long years. Even though COVID-19 will probably not vanish altogether, diminution of its virulence through generations of adaptation will render the virus more bearable and within normal capabilities of the health system to cope. For the private hospitals, unprecedented strides had been made in alleviating pressure of the public sector and supporting the Government's numerous initiatives to fight the epidemic. In St. Paul's, we have dedicated a whole ward to receive transferred convalescent patients from the HA, helped thousands of other public patients through PPP projects on specific diseases and CT/MRI examinations, provided tens of thousands of COVID vaccine shots, and supported a Community Isolation Facility for stable COVID elderly patients. In every step, we have closely followed Government direction and worked tirelessly to solve the novel problems that inevitably arose. SPH has been consistently appreciated as one of the most helpful private hospitals by the other side.

At the same time, we have kept our steadfast commitment to meet the needs of our private patients and private doctors despite all the challenges. We have treated thousands of COVID positive private out-patients; and to the extent our isolation rooms could accommodate, also COVID positive inpatients. Our vigilant COVID screening and infection control measures aim to strike a balance between preventing

outbreaks and undue hassle to patients and visiting doctors. So far, we believe we have achieved this balance through the nimble and timely fine-tuning of hospital policies in response to every twist and turn of the epidemic. With the epidemic continuing to decline, agreement has been reached for SPH to further cut back committed beds to receive HA patients, and services to private patients are quickly resuming normality.

Like everybody else however, we are challenged by manpower shortages. Hopefully this will gradually improve with time as the emigration wave abates. On the doctor's side, we are welcoming many joiners recently including our new Consultant Nephrologist, Surgeon, and two Cardiologists. Following expansion of our Cardiac Catheterization Laboratory from 1 to 2, as well as recent addition of ICU and HDU beds, the newly refurbished Oncology Centre for consultations and day chemotherapy will soon open. Planning and preparation for Radiotherapy service had commenced under a new multidisciplinary leadership team. Our Elderly Day Care Centre is set to receive more clients as normal life resumes in society. And the final phase of our Hospital Redevelopment Project, much hampered by COVID, is expected to see completion during the year. This will kick start sequential moves of certain services, and allow e.g. capacity expansion of our Renal Dialysis Centre which has been fully saturated for some time.

It remains for me to wish everybody good health and a most prosperous 2023!



SPH Pharmacy Department

Introduction

Oral chemotherapy has become an integral part of cancer treatment. These medications have a narrow therapeutic index and are often affected by food and/or drug interactions. Significant drug-drug interactions (DDIs) are more prevalent with oral than with parenteral anticancer medications because absorption issues that affect oral dosage forms are bypassed when drugs are administered intravenously.¹ DDIs are especially a concern in oncology as they may significantly reduce cancer treatment effectiveness, which in turn can jeopardize prognosis and increase mortality in patients.

DDIs are classified as pharmacokinetic or pharmacodynamic interactions. Pharmacokinetic interaction occurs when the absorption, distribution, metabolism, and/or excretion of the involved drugs are altered. Pharmacodynamic interactions alter the pharmacologic effect, which can be synergistic, additive, or antagonistic, and occur because of overlapping mechanisms of action or toxicities of the drugs. This article focuses primarily on pharmacokinetic DDIs.

Cytochrome P (CYP) 450 enzymes and P-glycoprotein (P-gp) transporter

One of the most common types of pharmacokinetic DDIs involves drug metabolism by CYP 450 enzymes. Approximately 70% of oral anticancer drugs, tyrosine kinase inhibitors (TKIs) in particular, are metabolized predominantly via CYP3A4. Simultaneous usage of strong CYP3A4 inhibitors, such as clarithromycin, azole antimycotics (itraconazole, ketoconazole, voriconazole), or HIV protease inhibitors (atazanavir, darunavir, lopinavir, ritonavir), may lead to elevated serum concentrations of TKIs. Furthermore, furanocoumarins contained in grapefruit strongly reduce the intestinal expression of CYP3A4, thus grapefruit products should be avoided by patients prescribed with a CYP3A4 substrate to avoid toxicities.² On the other hand, CYP3A4 inducers, such as carbamazepine, phenytoin, rifampicin, and St. John's wort would reduce plasma concentrations and thus loss of anti-tumour effect.

Cancer patients are often associated with additional comorbid conditions. Depression is more common in cancer patients compared with the general population, with an incidence of 8% to 24%.¹ Antidepressants that inhibit CYP2D6, which include bupropion, paroxetine, and fluoxetine, may reduce the clinical benefits of tamoxifen by decreasing metabolism via CYP2D6 to its active metabolite. Therefore, concomitant use of CYP2D6 inhibitors and tamoxifen should be avoided. Since antidepressants may cause withdrawal symptoms if abruptly stopped or rapidly reduced, an appropriate switch or cross-tapering schedule should be performed when necessary.

Another drug class commonly involved in DDIs include antiepileptic drugs that may be used for the treatment of comorbid seizure disorders in cancer patients. Concurrent use of oral anticancer therapies with known enzyme-inducing antiepileptics such as carbamazepine, phenobarbital and phenytoin should generally be avoided. Non-enzyme-inducing antiepileptic drugs, such as levetiracetam, topiramate, lamotrigine, pregabalin, and valproate, would be preferred.¹

Table 1. Summary of CYP 450 and P-gp mediated metabolism and interactions^{3,4}

Metabolism	Oral anticancer substrates	Common inhibitors	Common inducers
CYP1A2	Erlotinib	Ciprofloxacin Fluvoxamine	Cigarette smoking Montelukast Phenytoin Rifampicin
CYP2C9		Amiodarone Fluconazole	Carbamazepine Rifampicin
CYP2C19		Fluoxetine, Fluvoxamine Omeprazole Voriconazole	Phenytoin Rifampicin
CYP2D6	Tamoxifen	Bupropion, Fluoxetine, Paroxetine Terbinafine	
CYP3A4	Palbociclib, Ribociclib Everolimus Exemestane Tamoxifen TKI (Ceritinib, Crizotinib, Dasatinib, Erlotinib, Gefitinib, Ibrutinib, Imatinib, Lapatinib, Nilotinib, Osimertinib, Pazopanib, Regorafenib, Sorafenib, Sunitinib) Venetoclax	Aprepitant, Netupitant Azole antimycotics (Itraconazole, Ketoconazole, Voriconazole) Ciprofloxacin Clarithromycin, Erythromycin Diltiazem, Verapamil Dronedarone Fluvoxamine Grapefruit juice HIV protease inhibitors (Atazanavir, Darunavir, Lopinavir, Ritonavir)	Carbamazepine, Phenobarbital, Phenytoin Rifampicin St. John's wort
P-gp	Everolimus Pazopanib	Amiodarone, Dronedarone Clarithromycin, Erythromycin Cyclosporin Itraconazole, Ketoconazole Ritonavir Verapamil	

Gastric acid suppressants

Proton pump inhibitors (PPIs), histamine 2-receptor antagonists (H2RAs), and antacids affect the bioavailability of oral anticancer agents by altering the gastric pH. TKIs are mostly affected as they are weakly basic and are optimally absorbed under an acidic environment.¹ The use of acid suppressive agents would elevate the pH, significantly decreasing the solubility and absorption of TKIs, leading to reduced efficacy. Among the gastric acid suppressants, antacids not only affect the acidity but also the binding of drugs due to the presence of cations in them. Polyvalent cations in antacid formulations may form insoluble chelate complex with medications.⁵ These chelates are poorly absorbed, reducing the bioavailability of the substrate medication.

The concomitant use of PPIs with acalabrutinib, dacomitinib, dasatinib, erlotinib, neratinib, nilotinib, pazopanib, and sotorasib should be avoided. Due to the prolonged effect of PPIs on gastric pH, separating administration is unlikely to be an adequate means of avoiding the interaction. A recent systematic review and meta-analysis supports the evidence of possible negative survival outcomes from the combination of gastric acid suppressants and oral anticancer drugs.⁶ Studies have also found that the co-administration of erlotinib with the PPI omeprazole decreased erlotinib AUC by 46%. Another study has also found that the co-administration of erlotinib with ranitidine, an H2RA, decreased erlotinib AUC and Cmax by 33% and 54%, respectively, but when administered separately, by 15% and 17%, respectively, which highlights the importance of administering such agents in a staggered manner.⁷

Table 2. Management recommendations for gastric acid suppressants with oral anticancer drugs⁷⁻¹⁶

	PPI	H2RA	Antacid
BCR-ABL TKIs			
Dasatinib	X	X	Administer antacids 2 hours before or 2 hours after dasatinib.
Nilotinib	X	Administer nilotinib at least 2 hours before or 10 hours after H2RA.	Administer antacids 2 hours before or 2 hours after nilotinib.
Bruton TKIs			
Acalabrutinib	X	Administer acalabrutinib capsules 2 hours before H2RA. No action is required if acalabrutinib tablets are co-administered with H2RAs.	Separate the administration by at least 2 hours.
Cyclin-dependent protein kinases (CDK) inhibitors			
Palbociclib	Take palbociclib in capsule form with food to minimize the interaction or consider tablet form which is not altered by PPI.	✓	✓
Epidermal growth factor receptor (EGFR) TKIs			
Dacomitinib	X	Administer dacomitinib at least 6 hours before or 10 hours after H2RA.	✓
Erlotinib	X	Avoid if possible. If combination is necessary, erlotinib should be dosed once daily, 10 hours after and at least 2 hours before H2RA.	Pharmacokinetics have not been evaluated. Separate the administration by several hours if combination is necessary.
Gefitinib	Avoid if possible. If combination is necessary, administer gefitinib 12 hours after administration of the PPI or 12 hours before the next dose of the PPI, and closely monitor clinical response to gefitinib.	Administer gefitinib at least 6 hours before or 6 hours after administration of H2RA, and closely monitor clinical response to gefitinib.	Administer gefitinib at least 6 hours before or 6 hours after administration of antacids, and closely monitor clinical response to gefitinib.
Neratinib	X	Administer neratinib at least 2 hours before or 10 hours after H2RA.	Separate the administration by giving neratinib at least 3 hours after antacids.
Kirsten rat sarcoma (KRAS) inhibitor			
Sotorasib	X	X	Administer sotorasib 4 hours before or 10 hours after antacids.
Vascular endothelial growth factor receptor (VEGFR) TKIs			
Pazopanib	X	X	Avoid if possible. Separate the administration by several hours if combination is necessary.

X: Combination should be avoided

✓: Combination should not cause significant drug interactions

Anticoagulants

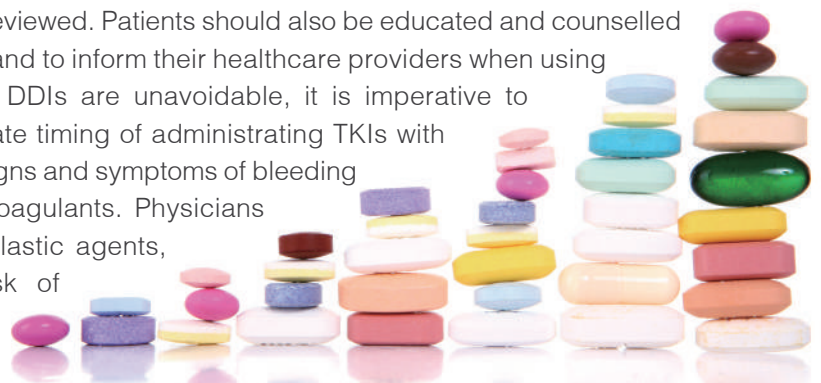Patients with cancer are found to have a 4-8 fold higher risk of venous thromboembolism development in comparison with the general population.¹ Warfarin and direct oral anticoagulants are used for long term treatment and are subject to multiple pharmacokinetic interactions. For example, all direct oral anticoagulants are metabolized by P-gp, with additional CYP3A4 metabolism for apixaban and rivaroxaban.

Bicalutamide, capecitabine, ceritinib, dasatinib, gefitinib, imatinib, and tamoxifen have been documented to increase warfarin exposure.¹ In particular, concomitant use of tamoxifen with warfarin is contraindicated in certain indications. The primary mechanism of this interaction is likely due to the inhibition of CYP2C9 enzymes, which accounts for most of the metabolism of S-warfarin, the more potent enantiomer of warfarin.¹⁷ Case reports and studies have shown that the concomitant administration of warfarin with tamoxifen or capecitabine has been associated with substantial elevations in the international normalized ratio (INR), clinically significant bleeding episodes, and even death.¹⁸⁻²¹ Another significant DDI is documented between bicalutamide and warfarin. The exact mechanism for interaction has not been fully investigated, but in vitro studies have found that bicalutamide can displace coumarin anticoagulants from their protein binding sites.²² Such protein binding interaction increases the concentrations of unbound anticoagulant, which may result in toxic effects of warfarin. If the above-mentioned agents are to be used concomitantly with warfarin, INR should be monitored closely and proactive dose adjustment should be considered.

Table 3. Summary of CYP 450 and P-gp mediated metabolism and interactions of oral anticancer drugs with anticoagulants⁴

Metabolism	Anticoagulant substrates	Oral anticancer inhibitors	Oral anticancer inducers
CYP2C9	Warfarin	Tamoxifen (weak) Capecitabine (weak)	Apalutamide Enzalutamide
CYP3A4	Apixaban Rivaroxaban	Ceritinib Imatinib Nilotinib	Apalutamide Dabrafenib Enzalutamide
P-gp	Apixaban Dabigatran Edoxaban Rivaroxaban	Enzalutamide Lapatinib Neratinib Osimertinib	Apalutamide

There are more and more developments and usage of oral anticancer medications as cancer is increasingly becoming a chronic condition. Oral anticancer medications have an increased risk for DDIs with other medications which patients may start or stop. Therefore, prior to initiation or upon changes of oral anticancer medications, the patient's complete medication profile should be obtained and thoroughly reviewed. Patients should also be educated and counselled on potential DDIs of their oral anticancer medications and to inform their healthcare providers when using other prescription or over-the-counter drugs. When DDIs are unavoidable, it is imperative to provide clear usage guidance, such as the appropriate timing of administering TKIs with respect to acid suppressive therapy or monitoring for signs and symptoms of bleeding when using certain oral anticancer drugs with anticoagulants. Physicians should be cognizant of potential DDIs with antineoplastic agents, especially oral agents, thereby mitigating the risk of reduced efficacy or increased toxicity.

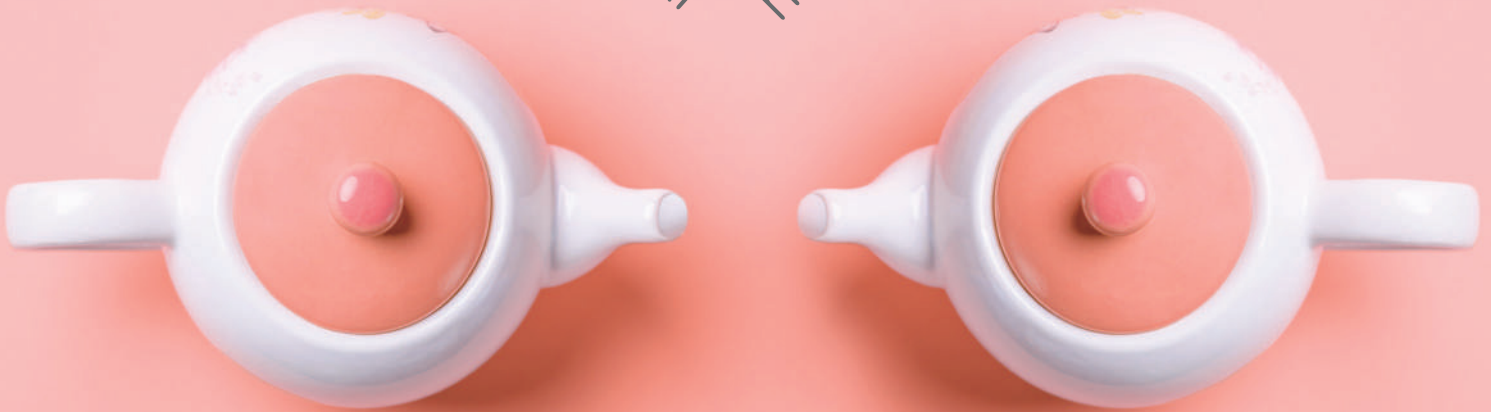

References:

- Rogala, B. G., Charpentier, M. M., Nguyen, M. K., Landolf, K. M., Hamad, L., & Gaertner, K. M. Oral Anticancer Therapy: Management of Drug Interactions. *Journal of oncology practice*. 2019; 15(2), 81–90.
- Schlichtig, K., Dürr, P., Dörje, F., & Fromm, M. F. New Oral Anti-Cancer Drugs and Medication Safety. *Deutsches Arzteblatt international*. 2019; 116(46): 775–782.
- Campen, C. J., Vogel, W. H., & Shah, P. J. Managing Drug Interactions in Cancer Therapy: A Guide for the Advanced Practitioner. *Journal of the advanced practitioner in oncology*. 2017; 8(6), 609–620.
- The Food and Drug Administration. Drug Development and Drug Interactions | Table of Substrates, Inhibitors and Inducers. US Food and Drug Administration. [Internet]. 2022 [updated 2022 August 24; cited 2022 December 3]. Available from: <https://www.fda.gov/drugs/drug-interactions-labeling/drug-development-and-drug-interactions-table-substrates-inhibitors-and-inducers>
- Patel, D., Bertz, R., Ren, S., Boulton, D. W., & Nágárd, M. A Systematic Review of Gastric Acid-Reducing Agent-Mediated Drug-Drug Interactions with Orally Administered Medications. *Clinical pharmacokinetics*. 2020; 59(4), 447–462.
- Indini, A., Petrelli, F., Tomasello, G., Rijavec, E., Facciorusso, A., Grossi, F., & Ghidini, M. Impact of Use of Gastric-Acid Suppressants and Oral Anti-Cancer Agents on Survival Outcomes: A Systematic Review and Meta-Analysis. *Cancers*. 2020; 12(4), 998.
- Tarceva (erlotinib). Prescribing Information. Genentech USA, Inc. October 2016.
- Sprycel (dasatinib). Prescribing Information. Bristol-Myers Squibb Company. September 2016.
- Tasigna (nilotinib). Prescribing Information. Novartis Pharmaceuticals Corporation. March 2018.
- Calquence (acalabrutinib) capsules. Prescribing Information. AstraZeneca Pharmaceuticals LP. October 2017.
- Ibrance (palbociclib) tablet. Prescribing Information. Pfizer Inc. November 2019.
- Vizimpro (dacomitinib). Prescribing Information. Pfizer Inc. December 2020.
- Iressa (gefitinib). Prescribing Information. AstraZeneca Pharmaceuticals LP. May 2021.
- Nerlynx (neratinib). Prescribing Information. Puma Biotechnology, Inc. February 2020.
- Lumkras (sotorasib). Prescribing Information. Amgen Inc. May 2021.
- Votrient (pazopanib). Prescribing information. GlaxoSmithKline. June 2014.
- Boruban, M. C., Yasar, U., Babaoglu, M. O., Sencan, O., & Bozkurt, A. Tamoxifen inhibits cytochrome P450 2C9 activity in breast cancer patients. *Journal of chemotherapy (Florence, Italy)*. 2006; 18(4), 421–424.
- Givens, C. B., Bullock, L. N., & Franks, A. S. Safety of concomitant tamoxifen and warfarin. *The Annals of pharmacotherapy*. 2009; 43(11), 1867–1871.
- Panahi, L., Saenz li, J. A., Nguyen, N., Udeani, G., & Surani, S. Hypercoagulation from Concomitant Administration of Tamoxifen and Warfarin. *Cureus*. 2020; 12(5), e8114.
- Mishra, D., Paudel, R., Kishore, P. V., Palaian, S., Bista, D., & Misra, P. Interaction between warfarin and tamoxifen: a case report. *Kathmandu University medical journal (KUMJ)*. 2007; 5(1), 105–107.
- Xeloda (capecitabine). Prescribing Information. Genentech Inc. February 2019.
- Casodex (bicalutamide). Prescribing Information. AstraZeneca Pharmaceuticals LP. November 2017.



Surgical management of



axilla in **BREAST CANCER** patient

Breast cancer has become the most common cancer among women in Hong Kong and its incidence has tripled over the last two decades. According to the Hong Kong Cancer Registry, 1 in every 14 women develops breast cancer in her lifetime and 13 women are diagnosed with breast cancer every day on average. Treatment of breast cancer has revolutionized in the last century contributing to improved survival. Clinical trials have been conducted all over the world, resulting in a continuous refinement of both surgical and oncological treatment. One of the rapidly developing area is axillary surgery.

In the past, all patients received axillary lymph node dissection (ALND) regardless of nodal status [1]. ALND is associated with significant morbidity including lymphedema, impaired shoulder movement and arm sensation, leading to considerable impact on quality of life [2,3]. The overall incidence of lymphedema varies from 10-30% [4]. Petrek et al. suggested the rate of lymphedema can be up to 50% at 20 years long-term follow-up, which could be relevant to patients undergoing multimodality treatment, for whom prolonged survival could permit manifestation of lymphedema[5].

From axillary dissection to sentinel lymph biopsy

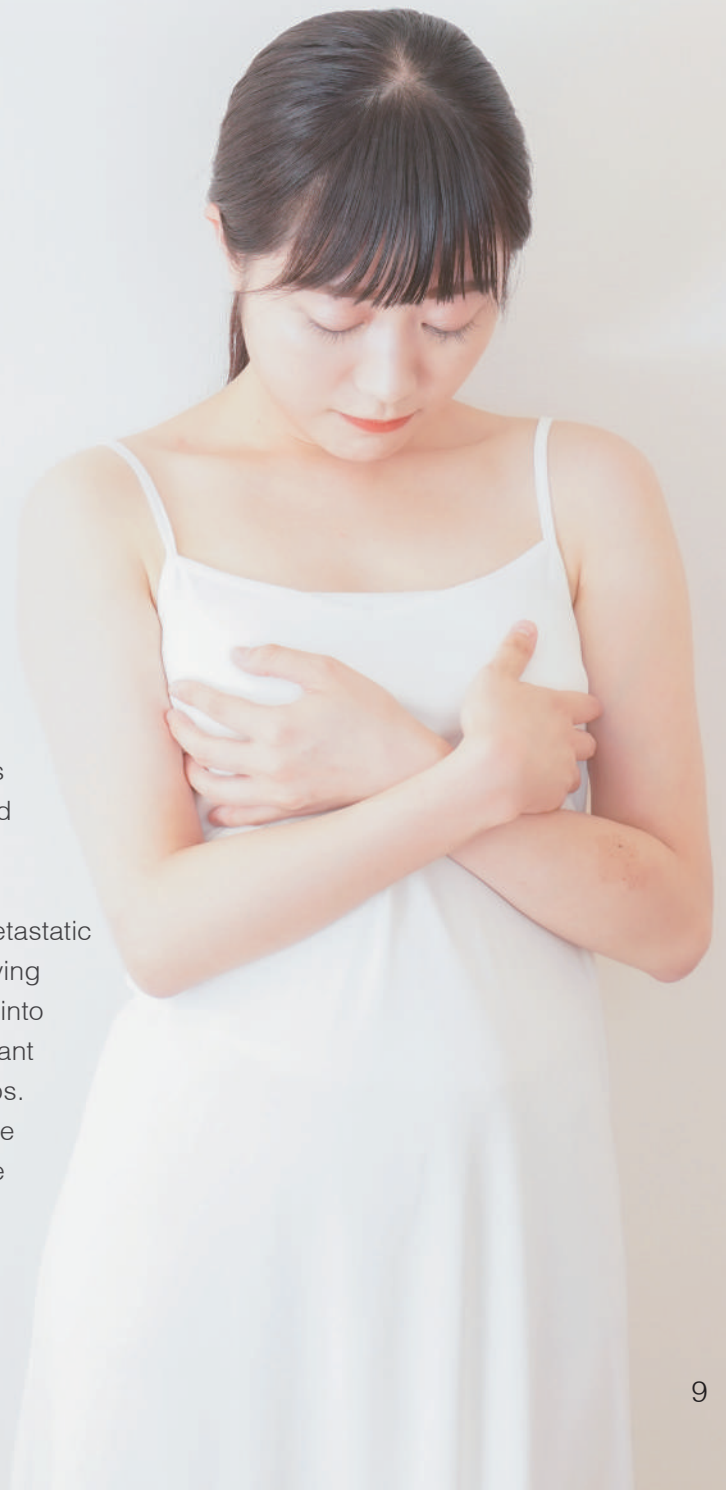
In recent decades, the role of axillary surgery in breast cancer is more on staging and prognostic purpose rather than therapeutic. The use of sentinel lymph node biopsy (SLNB) in patients with no clinical evidence of axillary lymph node metastasis has been employed based on results from clinical trials. The NSABP B32 trial and the Milan trial randomized patients with clinically node-negative disease and a negative SLNB into two groups, immediate ALND versus no further surgery. No significant difference in overall survival (OS), disease-free survival (DFS) or regional recurrence (RR) between both groups were observed [6, 7]. These results demonstrated that ALND in patients with negative SLNB does not improve disease control and survival, and SLNB was ultimately established as standard treatment for clinically node negative patients in 1990s [6, 7].

Management of positive sentinel lymph node

When metastatic disease is found in SLN, management varies according to extent of involvement. Nodal involvement is classified into macrometastatic (>2mm), micrometastasis (0.2-2mm) and isolated tumour cells (ITC) (<0.2mm). Although presence of micrometastasis in SLN is associated with decreased OS [8], ALND does not confer survival benefit or better regional control. In the IBCSG 23-01 trial, 931 patients with tumour ≤ 5 cm and micrometastasis or ITC on SLNB were randomized to ALND versus no further axillary surgery. After a median follow-up of 9.7 years, the authors could not demonstrate any significant difference in OS, DFS or recurrence [9]. Similar result was reported in AATRM 048/13 trial which randomized 247 patients with invasive breast cancer (size < 3.5 cm) and micrometastatic SLN to either ALND or no further surgery, after breast conserving surgery (BCS) and SLNB [10]. These trials suggested that ALND in micrometastatic SLN is not justified as it has no impact on survival.

ALND can be omitted even in selected patients with macrometastatic SLN. The ACSOG Z0011 trial randomized 856 patients receiving BCS with tumour ≤ 5 cm with less than 2 positive SLNs, into ALND versus no ALND. After a 10-year follow-up, no significant difference in RR and DFS was found between both groups. The authors concluded that ALND did not confer an advantage in this group of patients given they received standard whole breast irradiation and adjuvant systemic therapy [11]. ALND can therefore be safely omitted in patients fulfilling all the above mentioned criteria, and this has become the standard practice since 2010s.

The role of axillary radiotherapy (RT) as an alternative to ALND has also been studied in various trials. The AMAROS trial analysed 1425 patients with tumour ≤ 5 cm, clinically negative axilla, and at least 1 metastatic SLN, after either mastectomy or BCS. Patients were randomized to receive either ALND or axillary RT. Results at a medial follow-up of 6.1 years showed similar DFS, OS and axillary recurrence, while a lower risk of lymphedema in the axillary RT group [12]. This was echoed by the OTOASOR trial which involved 2073 patients with tumour ≤ 3 cm and clinically node-negative disease, receiving either ALND or RNI. After a 8-year follow-up, no significant difference of axillary recurrence, DFS and OS was found [13]. These results suggested axillary RT being non-inferior to ALND after positive SLN in selected group of patients.



Management of axilla after neoadjuvant therapy

Neoadjuvant systemic therapy is increasingly used in high-risk breast cancer such as triple negative and Her2 positive disease. Downstaging in both breast and axillary disease has been observed after neoadjuvant therapy. A pathological complete response (pCR) in node positive cases is reported in 40% of all patients and 60-70% of patients with Her2 positive disease [14, 15]. This subjects the traditional practice of routine ALND after neoadjuvant systemic therapy into question. Some evidence suggested primary chemotherapy can modify lymphatic drainage pattern causing differential downstaging between SLNs and non-SLNs, potentially leading to concern on false negative results in SLNB and difficulty in SLN identification.

Reports from trials revealed false negative rates (FNR) in the range of 8-11% for SLNB after neoadjuvant systemic therapy for patients with clinically node negative disease (cN0) at diagnosis, comparable to a FNR up to 10% in primary SLNB setting [16, 17]. In the NSABP B27 trial, the overall FNR was 11% but lower when dual tracer SLN localization with blue dye and radioisotope (8%) were used compared with blue dye alone (14%) [18]. The GANEA trial included both node negative and node positive patients with FNR of 9.4% in cN0 patients [19]. Investigators from MD Anderson Cancer Center found a relatively low FNR in SLNB after neoadjuvant systemic therapy (5.9%), which was comparable to prechemotherapy SLNB (4.1%) (p=0.39) [20]. Identification rate (IFR) of SLN in these three trials ranges from 85-97%, which is again comparable to an IFR of >90% in primary SLN setting. These results support the use of SLNB as the standard axillary staging procedure in patients with cN0 breast cancer after neoadjuvant systemic therapy.

For patients with initial node positive disease being downstaged after neoadjuvant systemic therapy, use of SLNB remains controversial due to concern on FNR. Several trials were conducted to address the tissue including the NSABP B27 trial, SENTINA trial, ACOSOG Z1071 trial, SN FNAC study which looked at FNR in cN1-N2 patients downstaged to cN0 after neoadjuvant systemic treatment. The reported FNR was 10.7%, 14.2%, 12.6% and 8.5% respectively, with lower rates if more than 3 SLNs were harvested (10% in ACOSOG Z1071 trial), or if dual agent SLN localization with radioisotope and blue dye were used [21]. The importance of the number of SLNs removed was highlighted in a recent meta-analysis analysing 1921 patients with cN+ disease

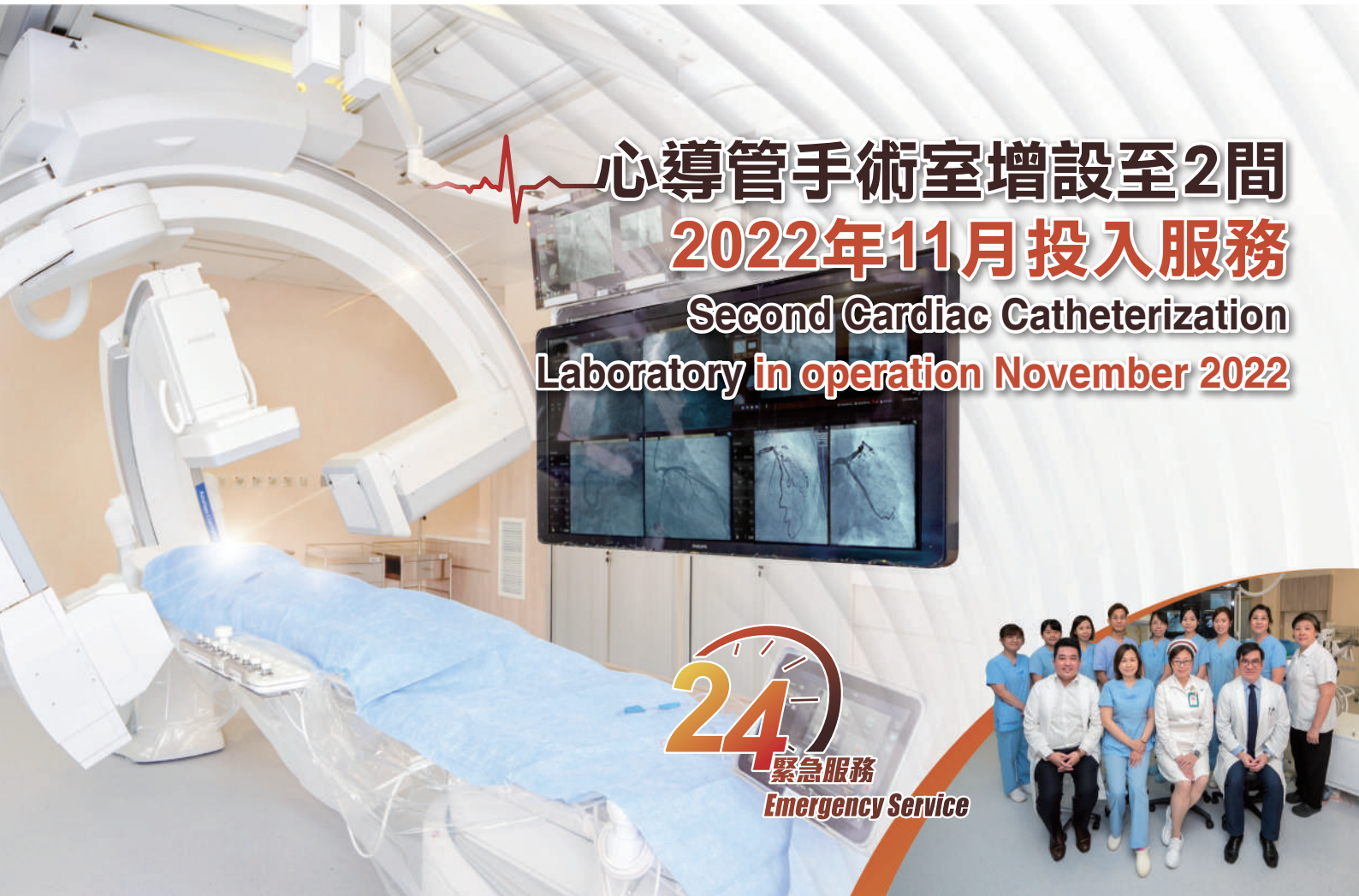in 13 studies. The FNR rate was found to decrease from 20% to 12% and 4% with 1, 2 and 3 or more lymph nodes were removed [22].

Another way to reduce FNR in patients with initial node positive disease is through marking the biopsied metastatic node before neoadjuvant therapy and removing it in SLNB. Caudle and colleagues reported a FNR of 1.4% when both SLNs and the marked lymph node were examined pathologically, compared with 10.1% when only SLNs were evaluated (p=0.03) [23]. The procedure combining resection of a previously proven metastatic node together with SLNB was called targeted axillary dissection (TAD). Based on these results, the NCCN guideline 2018 suggested SLNB can be offered to selected initial cN+ patients who were downstaged to cN0 after neoadjuvant systemic therapy using TAD [24].

There is a constant search for the best-suited procedure in various clinical settings with maximal effectiveness and minimal morbidity. On-going trials are in progress and further changes in axillary surgery are expected. In a few years, we will be performing less ALND and even omit axillary surgery in selected patients.

References:

1. Early Stage Breast Cancer: Consensus Statement. NIH Consensus Development Conference, June 18-21, 1990. *Cancer Treat Res* (1992) 60:383-93.
2. Rosses DF, Brooks AD, Harris MN, Shapiro RL, Mitnick J. Complication of Level I and II Axillary Dissection in the Treatment of Carcinoma of the Breast. *Ann Surg* (1999) 230(2):194-201.
3. Goyal A, Newcombe RG, Chhabra A, Mansel RE. Morbidity in Breast Cancer Patients With Sentinel Node Metastasis Undergoing Delayed Axillary Lymph Node Dissection (ALND) Compared With Immediate ALND. *Ann Surg Oncol* (2008) 15(1):262-7.
4. Pain SJ, Purushotham AD. Lymphoedema following surgery for breast cancer. *Br J Surg* 2000; 87: 1128-41
5. Petrek JA, Senie RT, Peters M, et al. Lymphedema in a cohort of breast carcinoma survivors 20 years after diagnosis. *Cancer* 2001;92: 1368-77.
6. Krag, D.N.; Anderson, S.J.; Julian, T.B.; Brown, A.M.; Harlow, S.P.; Costantino, J.P.; Ashikaga, T.; Weaver, D.L.; Mamounas, E.P.; Jalovec, L.M.; et al. Sentinel-lymph-node resection compared with conventional axillary-lymph-node dissection in clinically node-negative patients with breast cancer: Overall survival findings from the NSABP B-32 randomised phase 3 trial. *Lancet Oncol*. 2010, 11, 927-933.
7. Veronesi U, Viale G, Paganelli G, et al. Sentinel lymph-node biopsy in breast cancer: ten-year results of a randomized controlled study. *Ann Surg* 2010;251(4):595-600.
8. de Boer M, van Dijk JA, Bult P, Borm GF, Tjan-Heijnen VC. Breast Cancer Prognosis and Occult Lymph Node Metastases, Isolated Tumor Cells, and Micrometastases. *J Natl Cancer Inst* (2010) 102(6):410-25.
9. Galimberti, V.; Cole, B.F.; Viale, G.; Veronesi, P.; Vicini, E.; Intra, M.; Mazzarol, G.; Massarut, S.; Zgajnar, J.; Taffurelli, M.; et al. Axillary dissection versus no axillary dissection in patients with breast cancer and sentinel-node micrometastases (IBCSG 23-01): 10-year follow-up of a randomised, controlled phase 3 trial. *Lancet Oncol*. 2018, 19, 1385-1393
10. Solá, M.; Alberro, J.A.; Fraile, M.; Santesteban, P.; Ramos, M.; Fabregas, R.; Moral, A.; Ballester, B.; Vidal, S. Complete axillary lymph node dissection versus clinical follow-up in breast cancer patients with sentinel node micrometastases: Final results from the multicenter clinical trial AATRM 048/13/2000. *Ann. Surg. Oncol.* 2013, 20, 120-127.
11. Giuliano, A.E.; Ballman, K.; McCall, L.; Beitsch, P.; Whitworth, P.W.; Blumentcranz, P.; Leitich, A.M.; Saha, S.; Morrow, M.; Hunt, K.K. Locoregional Recurrence After Sentinel Lymph Node Dissection With or Without Axillary Dissection in Patients With Sentinel Lymph Node Metastases: Long-term Follow-up From the American College of Surgeons Oncology Group (Alliance) ACOSOG Z0011 Randomized Trial. *Ann. Surg.* 2016, 264, 413-420.
12. Donker, M.; van Tienhoven, G.; Straver, M.E.; Meijnen, P.; van de Velde, C.J.; Mansel, R.E.; Cataliotti, L.; Westenberg, A.H.; Klinkenbijl, J.H.; Orzalesi, L.; et al. Radiotherapy or surgery of the axilla after a positive sentinel node in breast cancer (EORTC 10981-22023 AMAROS): A randomized, multicentre, open-label, phase 3 non-inferiority trial. *Lancet Oncol*. 2014, 15, 1303-1310
13. Savolt, Á.; Péley, G.; Polgár, C.; Udvarhelyi, N.; Rubovszky, G.; Kovács, E.; Gyórfy, B.; Kásler, M.; Mátrai, Z. Eight-year follow up result of the OTOASOR trial: The Optimal Treatment Of the Axilla—Surgery Or Radiotherapy after positive sentinel lymph node biopsy in early-stage breast cancer: A randomized, single centre, phase III, non-inferiority trial. *Eur. J. Surg. Oncol.* 2017, 43, 672-679.
14. Boughey JC, Ballman KV, Le-Petross HT, et al. Identification and resection of clipped node decreases the false-negative rate of sentinel lymph node surgery in patients presenting with node-positive breast cancer (T0-T4, N1-N2) who receive neoadjuvant chemotherapy: results from ACOSOG Z1071 (Alliance). *Ann Surg* 2016;263:802-7.
15. Lim GH, Teo SY, Gudi M, et al. Initial results of a novel technique of clipped node localization in breast cancer patients postneoadjuvant chemotherapy: Skin Mark clipped Axillary nodes Removal Technique (SMART trial). *Cancer Med* 2020;9:1978-85.
16. Harlow SP, Krag DN, Julian TB, Ashikaga T, Weaver DL, Feldman SA, et al. Prerandomization Surgical Training for the National Surgical Adjuvant Breast and Bowel Project (NSABP) B-32 trial: a randomized phase III clinical trial to compare sentinel node resection to conventional axillary dissection in clinically node-negative breast cancer. *Ann Surg*. 2005;241(1):48-54.
17. Krag DN, Anderson SJ, Julian TB, Brown AM, Harlow SP, Costantino JP, et al. Sentinel-lymph-node resection compared with conventional axillary-lymph-node dissection in clinically node-negative patients with breast cancer: overall survival findings from the NSABP B-32 randomised phase 3 trial. *Lancet Oncol*. 2010;11(10): 927-33.
18. Mamounas EP, Brown A, Anderson S, et al. Sentinel node biopsy after neoadjuvant chemotherapy in breast cancer: results from National Surgical Adjuvant Breast and Bowel Project Protocol B-27. *J Clin Oncol*. 2005;23(12):2694-2702.
19. Classe JM, Bordes V, Campion L, et al. Sentinel lymph node biopsy after neoadjuvant chemotherapy for advanced breast cancer: results of Ganglion Sentinel et Chimiothérapie Néoadjuvante, a French prospective multicentric study. *J Clin Oncol*. 2009;27(5):726-732.
20. Hunt KK, Yi M, Mittendorf EA, et al. Sentinel lymph node surgery after neoadjuvant chemotherapy is accurate and reduces the need for axillary dissection in breast cancer patients. *Ann Surg*. 2009;250(4):558-566.
21. Yan M, Abdil MA, Falson CB. Axillary management in breast cancer patients: a comprehensive review of the key trials. *Clin Breast Cancer*. 2018;18:1251-9.
22. Tee SR, Devane LA, Evoy D, et al. Meta-analysis of sentinel lymph node biopsy after neoadjuvant chemotherapy in patients with initial biopsy-proven node-positive breast cancer. *Br J Surg* 2018;105:1541-52.
23. Cabog lu N, Karanlık H, Kangal D, et al. Improved false-negative rates with intraoperative identification of clipped nodes in patients undergoing sentinel lymph node biopsy after neoadjuvant chemotherapy. *Ann Surg Oncol* 2018;25:3030-6.
24. Network NCC. Breast Cancer (Version 4.2022). ©2022 National Comprehensive Guidelines Network®NCCN®.




心導管手術室增設至2間
2022年11月投入服務
Second Cardiac Catheterization
Laboratory in operation November 2022

24
緊急服務
Emergency Service

INTRODUCTION


OF NEW FACES



Dr. Chan Man Yi
Resident Consultant Surgeon

Dear friends and colleagues, this is Justina Chan. It is my pleasure to join the St Paul's family as a new breast surgeon. I was trained in the New Territories West Cluster as a general surgeon before devoting my career to breast surgery. My special interest is in oncoplastic breast surgery and for this reason I underwent oversea-training in the Oxford University Hospitals few years ago. That has been an eye-opening experience which allowed me to work with experts from all over the world. In my free time, I enjoy movies, concerts and yoga. Looking forward to collaborating with all of you.

It is my honor to join the St. Paul's family. I graduated from The University of Hong Kong and completed my residency in Princess Margaret Hospital. I am a nephrologist and have special interest on the field of interventional nephrology and renal transplantation. By the way, I am a cat lover and I got two cats at home. I look forward to working with all of you in the future!



Dr. Lam Chung Man
Resident Consultant Nephrologist

2022

長期服務獎頒發儀式



何醫生是今年其中一位十年長期服務獎得獎者



三十及二十年長期服務獎得獎同事與管理層合照



聖保祿醫院於12月13日假本院演講廳舉行2022年長期服務獎頒發儀式，藉以感謝和表揚員工多年來的努力耕耘及貢獻。今年共4位同事獲得三十年長期服務獎及2位同事獲得二十年長期服務獎，而獲得十年長期服務獎的同事亦有36位。此外，醫務行政總監何兆煒醫生及副醫務總監李啟聰醫生分別獲得十年長期服務獎及長青服務獎。院方致送獎狀及紀念水晶給得獎者以表謝意，部門同事紛紛送上禮物和花束祝賀。多位同事上台分享得獎感受，回憶起昔日工作的苦與樂，並感激醫院多年來的提攜。院方今年共送出了超過500份幸運禮物，並在儀式的尾聲舉行終極幸運抽獎，各幸運兒得獎時心情興奮，場面高興熱鬧。



為迎接普天同慶的聖誕節，聖保祿醫院於12月13日假本院餐廳舉行聖誕聯歡會，讓員工暫時放下繁忙的工作，一同享受豐富的自助餐，彼此聯誼，送上問候祝福。餐飲膳食部及營養師精心預備佳餚美食，款式之多更可媲美酒店自助餐，院方亦安排了新穎有趣的攤位遊戲，各人均投入於遊戲之中，四周不時傳來歡笑聲，同事互相拍照留念，洋溢著濃厚的節日氣氛，眾同事均盡興而歸。

